

Clinical Case Presentation

Title:

*Fusobacterium Necrophorum* and *Prevotella Loescheii*: Unexpected Culprits of Necrotizing Pneumonia in a Patient with Lupus

Authors:

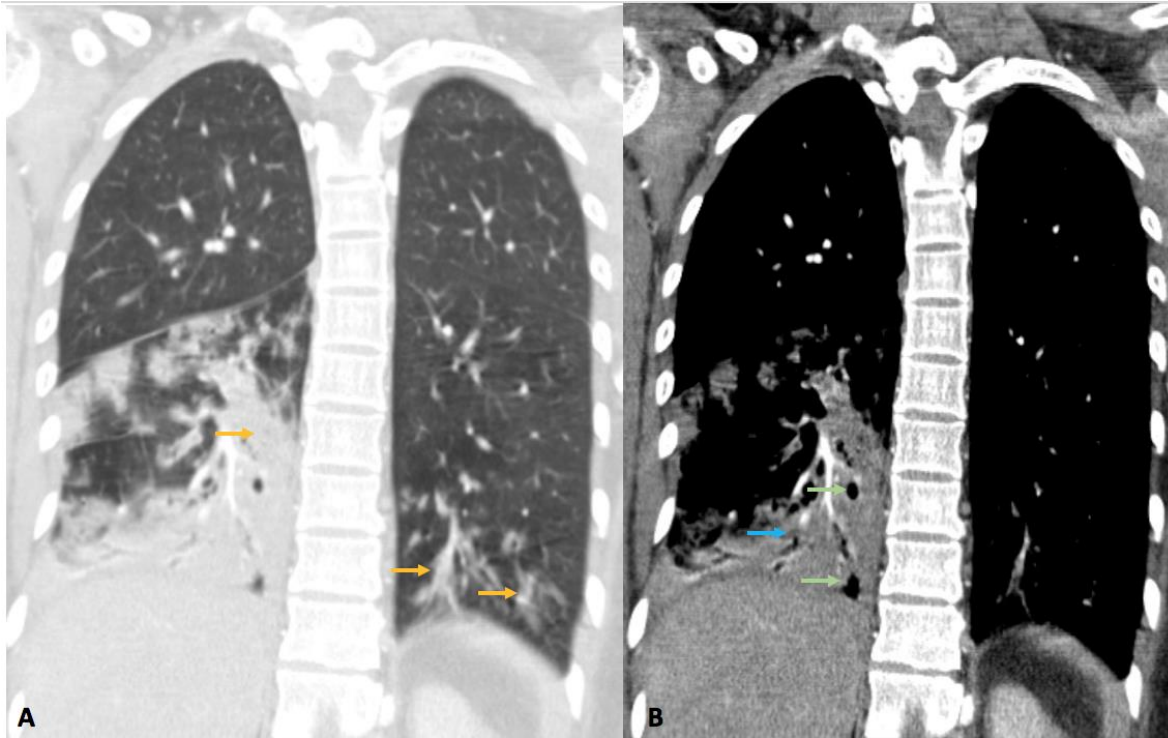
Vanessa Soetanto, MD, Sana Rashid, DO, Suzanne Atkin, MD.

Body:

Rarely is necrotizing pneumonia caused by both *Fusobacterium necrophorum* and *Prevotella loescheii*, gram-negative bacteria found in the oropharynx. We present a case of necrotizing pneumonia with bacteremia and bleeding in an immunocompromised patient.

A 29-year old woman with systemic lupus erythematosus on chronic corticosteroids and hydroxychloroquine presented with 3 days of fevers, hemoptysis and dyspnea. She took warfarin for antiphospholipid syndrome and was recently treated for oral ulcers due to *Herpes simplex virus-1* stomatitis. On exam, she was febrile, hypotensive, tachycardic, and tachypneic with adequate oxygenation on room air. Blood was seen in her oral cavity overlying notable gingivitis. Studies showed microcytic anemia, negative human immunodeficiency virus and quantiferon gold, and supra-therapeutic international normalized ratio (INR) of 15.9, for which warfarin was held. Chest x-ray revealed patchy consolidation at the right lung base concerning for pneumonia. Computed tomography (CT) scan of the chest showed a large consolidation within the right lower lobe with small cavities and scattered nodular densities surrounded by ground glass opacities in the right and left lower lobe suggesting aspiration (Figure 1). She was started on empiric intravenous antibiotics for necrotizing pneumonia and was transfused for a hemoglobin of 5.3 g/dL. Her INR decreased as her sepsis improved. Due to the high bleeding risk and improving clinical status, no surgical interventions were pursued. On hospital day 6, blood cultures sent from admission revealed *P. loescheii* and *F. necrophorum*. CT scan of the neck to assess for Lemierre's Syndrome showed patent vasculature and a 1.1 cm fluid collection in the oropharynx, supporting a periodontal source of necrotizing pneumonia. Her antimicrobial regimen was adjusted with continued improvement.

It is crucial to consider the host and take detailed history in tailoring initial antibiotic treatment. The patient's previous oral ulcers and gingivitis predisposed her to periodontal origins of infection.



*Figure 1. Computer tomography scan of the chest with contrast, coronal views. A There are multiple areas of nodular densities in the right and left lower lobes, and a large confluent consolidation in the right lower lobe (yellow arrows). B There are small areas of cavitations within the consolidations (green arrows), and areas of low perfusion (blue arrow), consistent with the diagnosis of necrotizing pneumonia.*